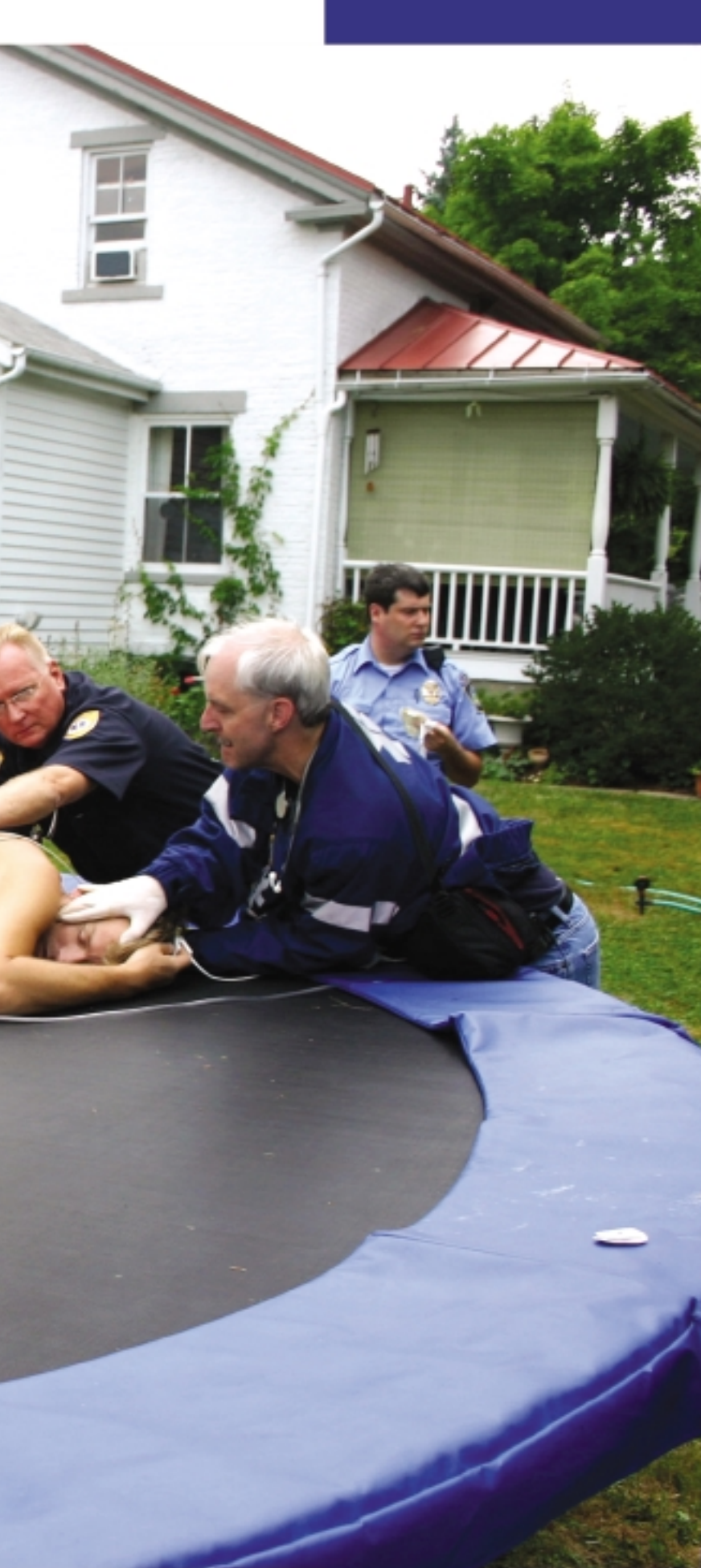

A photograph showing three paramedics in dark blue uniforms and gloves attending to a patient lying on their back on a black trampoline. The patient is wearing patterned shorts and has a white cloth covering their lower body. The paramedics are positioned around the patient, with one on the left, one in the middle, and one on the right. In the background, there is a white SUV with its rear door open, a blue bicycle, and a white house with a red roof. The scene is outdoors with trees and a lawn.

UNSTABLE PLATFORM

Trampoline injury requires
creative problem solving
to avoid iatrogenic injury



Story by Jay Carter, MSE, MD, FACEP,
& David Enzman, NREMT-P;

Photos by Bruce Graham, NREMT-P,
Hudson EMS Operations Manager

Extrication of patients from motor vehicle accidents is usually well covered in EMT courses, and EMS personnel gain expertise in this component of rescue operations—many calls, many scenarios, much extrication experience—early on in their careers. But a crew from Hudson (Ohio) EMS (HEMS), with a combined EMS experience totaling more than 100 years, responded to a call that presented a unique situation.

The call

The tones dropped for a man injured on a trampoline and unable to move. The man's wife had made the call to 9-1-1. The crew suspected a cervical spine injury from the start, and they anticipated putting the patient on a backboard and being off to the hospital in short order. In their minds, extricating and transferring a patient from a backyard trampoline would certainly be easier than removing someone from an upstairs bathroom, the bottom of the basement stairs or a small, subcompact car. Surprisingly, this was not the case.

On scene, Hudson EMS found a large, backyard trampoline, elevated three feet off the ground. The patient, an adult male, was lying on it, partially prone. His head was positioned near the edge of the canvas, and his feet were near the center (see [Photo 1](#), left). He was able to open his eyes and respond appropriately to questioning. He complained of some soreness in his neck. He denied any headache, change in vision, chest pain, shortness of breath, or abdominal, back or extremity pain. He also denied any numbness or tingling in his extremities. He stated that he had attempted to do a flip and had been unable to move since landing.

The physical exam revealed an awake patient who was oriented x 3. The patient had no obvious head or facial trauma, but complained of mild tenderness on palpation of the posterior

Photo 1: Responding to a backyard trampoline injury, crews work together as a team and use innovative methods to stabilize and prevent further injury to the patient.



Photo 2: Two cribbing towers, air bags and a backboard are placed beneath the markedly sagging trampoline canvas to elevate and stabilize the patient prior to further immobilization.



Photo 3: Post air-bag inflation, the patient is elevated to a non-sagging, horizontal position with the canvas stabilized to minimize motion.

neck. His chest was non-tender and without any crepitus. He had adequate bilateral breath sounds and no obvious respiratory distress. His abdomen and back were non-tender. The extremities were also non-tender and without any obvious deformity.

The crew observed no voluntary motion of the patient's hands or feet. Sensation to light touch was intact on the face, but absent from his chest, abdomen, back and extremities. The crew's clinical impression was of a cervical spine injury with resultant quadriplegia. With a safe scene

and the initial patient assessment completed, the crew's attention turned to immobilization.

Without anyone on it, a trampoline canvas is normally taut and level. However, loaded with the weight of an adult male, the canvas sagged significantly, almost 18 inches from a level plane. Additionally, although the trampoline surface looked firm, it wasn't; the canvas had significant spring to it. Any additional pressure applied caused it to bounce up and down, much like a water bed's surface.

It was clear that the patient had a significant, unstable cervical spine injury. The providers were concerned that any further motion could result in respiratory failure or death.

Initially, consistent with standard EMS practices, a backboard was placed on the trampoline, adjacent to the patient with the goal being to immobilize him without inflicting any further injury. The board was supported at each end, but the canvas and the patient sagged well below the level of the backboard. It looked like a bridge spanning a valley.

The crew considered placing providers on the trampoline, adjacent to the patient's shoulders, hips and legs, to both lift and logroll the patient onto the board—but quickly decided this was impractical. The amount of lifting, coupled with the instability and bouncing it would have caused, would have made adequate cervical immobilization impossible.

The EMS incident commander requested the Hudson Fire Department for assistance with patient extrication. The EMS and fire incident commanders, brainstorming and soliciting input from others on scene, evaluated several options and elected to construct an "elevator" (see Photos 2 and 3, above) to level and stabilize the trampoline and patient. The amount of lifting necessary to bring

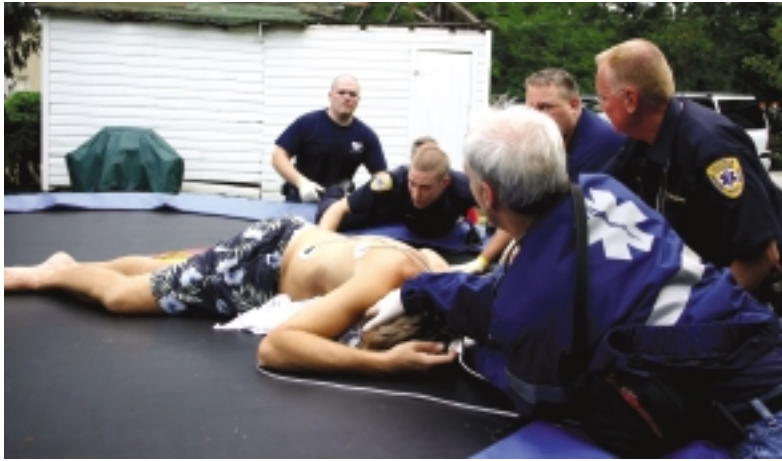

Photo 4: Logrolling a patient with a traumatic cervical spine injury warrants meticulous care to prevent the infliction of further injury or death.

the patient to a level position is evident in the pre- and post-inflation photos.

Two cribbing towers were placed beneath the patient. An inflatable air bag was placed on each tower, and a backboard was placed across the top of the air bags. With one crew stabilizing the patient from above and another crew stabilizing the elevator from below, the bags were slowly inflated.

The backboard beneath the trampoline canvas rose gently, lifting the patient's body up to a level, horizontal position. It formed a rigid platform beneath the patient and helped stabilize the neighboring region of canvas. The pa-

tient was then logrolled in a slow, controlled manner onto the backboard on top of the canvas (see [Photo 4](#), left).

The patient's head was initially found to be anteriorly positioned with lateral displacement and significant rotation. A single, smooth roll and positioning were desirable to regain neutral alignment and minimize the potential for inflicting further, iatrogenic injury. The patient's head was managed by the HEMS medical director, who had responded to the scene, and the patient's shoulders were managed by the EMS IC, who optimized the positioning of the patient's head, neck and shoulders.

To avoid hesitation or pause while logrolling the patient, the medical director cautioned the crews in advance not to stop the logroll mid-procedure for any reason. Although the patient did not experience any pain during the transfer, the providers noted bony crepitation while logrolling and positioning him.

After the patient was positioned on the board, a cervical collar was carefully applied, followed by head blocks. The patient's neurologic status was assessed both pre- and post-positioning. Fortunately, there was no deterioration in the patient's baseline condition, no sudden apnea and no sudden death. Unfortunately, there was no readily apparent improvement in the patient's quadriplegia. (Photo 5 [p. 88] illustrates the patient post-immobilization and ready for transport.)

The patient was placed on high-flow oxygen by mask to

augment his respiratory status, and two large-bore IVs were started to permit fluid resuscitation should the patient manifest spinal shock with hypotension and bradycardia. A fingerstick glucose level and ECG were obtained to rule out hypoglycemia or arrhythmia as possible precipitating factors for the event.

The medical director instructed providers to administer Phenergan, if needed, to treat nausea experienced by the patient during transport. Narcotic analgesics were also considered, but proved unnecessary. Throughout the call, the patient's pain was surprisingly minimal.

The crew included several "old-timers" who normally enjoy the challenge of performing invasive procedures, including intubation. But not during this call—not on this patient. Each of the seasoned providers later said they were thinking, "Please keep breathing," throughout the call.

Much like the prospect of field amputations, intubation of a patient with cervical trauma is a bridge that the insightful practitioner would prefer never to cross; the risk of inducing further injury or death is just too high.

Treatment options were mulled over before any action was taken so that if an intervention became necessary, the plan of action would already be in place and indecision would not delay treatment. Oral intubation, surgical cricothyrotomy and bag-valve-mask ventilation were all discussed. Paralytics and LMAs were not available for consideration.

Fortunately, no intervention was required. The patient remained conversant and had no respiratory distress throughout the call. After hospital arrival, the patient did eventually tire and subsequently received a tracheotomy and ventilator support. Following a stormy course, which included blood clots in his legs, pneumonia and cardiac arrest, he was ultimately weaned off the ventilator. Although he remains quadriplegic, he is currently in a spinal cord rehabilitation unit in Cleveland.

Spinal review

To fully understand the significance of this case and the extrication and immobilization procedures used, it's important to review spinal anatomy and discuss this patient's specific injury. The spine can be viewed as a structural support for the body. It comprises 33 vertebra (seven cervical, 12 thoracic, five lumbar, five sacrum and four coccyx). The vertebral bodies are strong, cylindrical bony structures that support an individual's weight.

Posterior to the vertebral bodies is a bony ring that protects the spinal cord it encompasses. The bodies are separated by disks that serve as shock absorbers for the spine and increase mobility. The ring has bony prominences that extend posteriorly and bilaterally. The posterior prominences can be felt as bumps down the center of your back. They serve as attachment points for muscles.

A multitude of possible spinal fractures exist, a review of

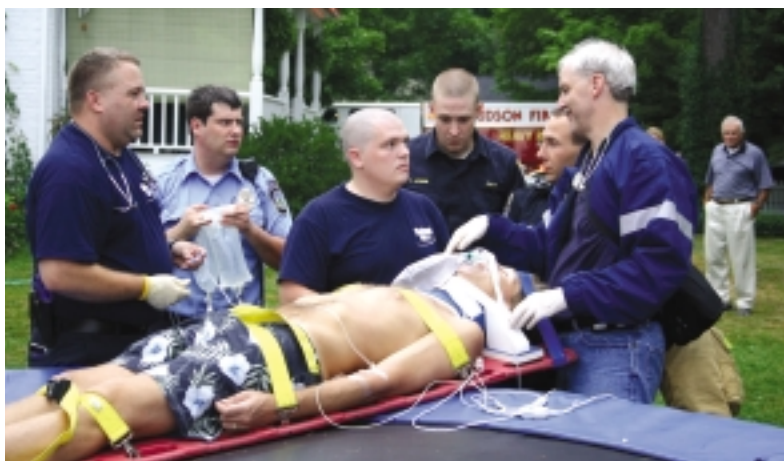

Photo 5: Neurovascular integrity is ascertained both prior to and following immobilization. Oxygen, fluids, monitoring and medications are instituted as warranted.

which is beyond the scope of this article. Of concern to EMS is the fact that some fractures may impinge on the spinal canal and the spinal cord within. Fractures may be unstable, permitting the bones to shift and to compress or sever the spinal cord.

Severed nerve fibers result in permanent loss of function. Compressed nerves may recover but, unfortunately, are prone to permanent injury. Damage to a motor nerve will result in paralysis of the muscle innervated by that nerve. In addition to para- or quadriplegia, motor nerve injury can result in respiratory insufficiency, or apnea. Damage to sensory nerves results in the loss of sensation,

pain and temperature.

The goal of prehospital cervical spine immobilization is to maintain the head and neck in a neutral position and prevent any motion from inducing or worsening nerve injury. C-spine protocols are designed to protect the patient with a known or potential neck injury, recognizing that once injury occurs, it's frequently irreversible and often devastating.

This patient sustained quadriplegia, which was evident during the crew's initial assessment. The concern for his breathing was due to the fact that the level at which the spine was injured determines the ability of the patient to breathe.

Breathing encompasses ventilation (i.e., moving air in and out of the lungs) and respiration (i.e., the exchange of gases between the alveoli and the blood). Ventilation is controlled subconsciously, with conscious override. You breathe without thinking about it but you can also take a deep breath or hold your breath, if you so desire.

Ventilation is so crucial to life that nature has built in redundancy, providing two separate neuromuscular mechanisms to make sure it happens. Nerve roots branch off the spinal cord at cervical levels C3, C4 and C5, forming the phrenic nerves. The right and left phrenic nerves travel down to innervate the diaphragm. The muscular diaphragm contracts, pulls downward and draws air into the lungs.

Additionally, the thoracic nerves, which branch off the spinal cord at thoracic levels T1 through T11, innervate the

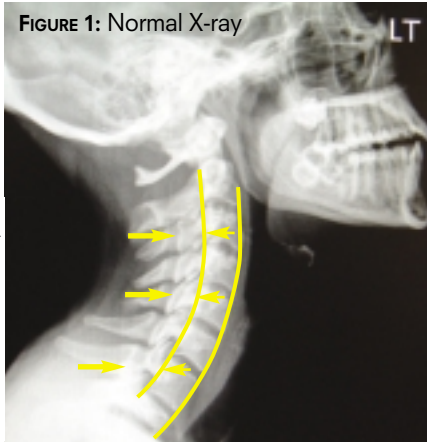


FIGURE 1: Normal X-ray

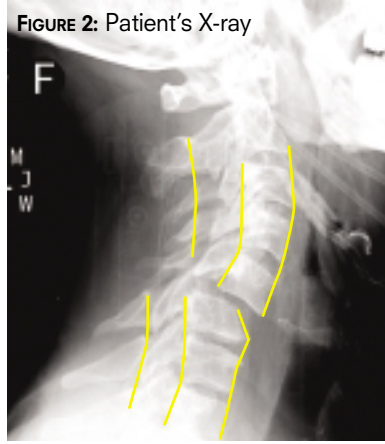


FIGURE 2: Patient's X-ray

FIGURE 1: In this normal cross table lateral cervical spine X-ray, the vertebral bodies are in proper alignment (yellow lines). Opposing arrows allow you to see the overlying vertebral bodies (3, 5 and 7) through which an uninjured, unimpeded spinal cord traverses.

FIGURE 2: This X-ray shows a fracture and an anterior subluxation (anterior displacement) on top of C5 on C6, the reason for this patient's quadriplegia. The spinal canal is significantly disrupted, thereby compressing or severing the spinal cord. The alignment of the vertebral bodies and the lumen of the spinal canal are highlighted by the yellow lines.

chest wall musculature. Muscular contraction increases the diameter and, hence, the volume of the thoracic cavity, again drawing air into the lungs. In both cases, muscular relaxation leads to exhalation.

A high cervical spinal injury (above C3) can disrupt neural control of both the phrenic and thoracic nerves, leading to cessation of respiration (apnea) and death. Injury below C3 and above T1 leaves the phrenic component of respiration intact while disrupting the thoracic component. Cord injury below T11 leaves both neural pathways intact, thereby not causing impaired ventilation. Based on the specific injury location, partial nerve disruption or unilateral impairment may also occur.

A normal lateral cervical spine X-ray is depicted in

Figure 1 (p. 89, above left). The skull, spine and teeth are recognizable landmarks. The solid vertebral bodies are seen stacked one on top of the next. Yellow lines, superimposed on the figure, demonstrate the smooth arc of the front and back edges of the vertebral bodies.

The arrows (overlying vertebral bodies 3, 5 and 7) mark the interior of the spinal canal, through which the spinal cord runs, just posterior to the vertebral bodies. On X-rays such as these, the bony structures that make up the spinal canal are well seen. The soft tissue comprising the spinal cord itself, however, is not actually seen within the canal. In any case, you should keep in mind that at the cervical level, the spinal cord fills the majority of the spinal canal space. The posterior spinous processes can be imagined to all point to-

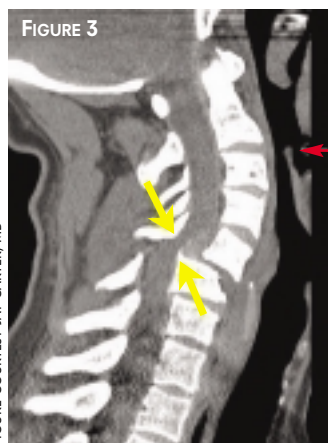


FIGURE 3: The CAT scan demonstrates marked narrowing of the spinal canal, which compressed the spinal cord at the C5–C6 level (see arrows). The black column of air anterior to the vertebral bodies is the trachea. The epiglottis is marked with a single red arrow. The mal-alignment evident is following field repositioning to a neutral position.

ward a single focal point.

This lateral cervical spine X-ray demonstrates the reason for this patient's quadriplegia (see [Figure 2](#), p. 89). He sustained both a fracture and an anterior subluxation of C5 on C6. Subluxation refers to the anterior displacement, or shift in position, of the C5 vertebral body on top of C6.

The spinal canal is significantly disrupted, thereby compressing or severing the spinal cord. The two anterior yellow lines again demonstrate the alignment of the vertebral bodies, highlighting the subluxation. The middle and posterior yellow lines outline the spinal canal, making the disruption readily apparent. Imagine the spinal canal as a vertically oriented pipe through which the spinal cord runs. In this case, the pipe is sawed in half, and the top section is shifted significantly forward, markedly narrowing the lumen through which the cord must run.

[Figure 3](#) is an image from a CAT (computed axial tomography) scan performed on this patient's cervical spine. The CAT scan permits such soft tissues as the spinal cord to be well visualized. This view represents what it would look like if the patient were sliced down the midline, dividing the body into right and left halves, and you could then view the cut surface.

The white vertebral bodies are again seen stacked one upon another, with the C5 body displaced anteriorly. The white posterior spinous processes are also easily seen. The spinal canal is the space between them. The severe narrowing of the canal, which pinches on and either compresses or severs the spinal cord, is marked with opposing arrows and can be readily appreciated. The space (lumen/spinal canal) remaining for the spinal cord is markedly reduced, resulting in the catastrophic neurologic injury seen in this patient.

Of incidental note are the patient's trachea and epiglottis, both of which are also well visualized on this image. The trachea appears as a black (air-filled) column anterior to the vertebral bodies. The epiglottis is marked with a single, white arrow.

The significant narrowing of the spinal canal and the resultant compression of the spinal cord seen in these images is particularly noteworthy when you realize that these images were obtained in the emergency department. This was what it looked like after the patient's head was carefully positioned and collared by EMS, and after they had logrolled him onto the backboard for immobilization and extrication. Further narrowing may have been present prior to the positioning and

immobilization performed on scene.

Additionally, both the lateral displacement and the rotation of the patient's head and neck, evident on the initial physical exam, were corrected on scene and are not evident on these views. To follow the pipe analogy, imagine shifting the top section of pipe not only forward but also sideways to envision what this patient's cervical spine looked like prior to prehospital care.

The patient's cervical injury was primarily at the C5-C6 level. The phrenic nerves, originating *above* the level of the injury, continued to work, innervating his diaphragms. The patient's spinal cord was disrupted above the level of the thoracic nerves, T1-T11, resulting in paralysis of the chest wall musculature, as well as everything else below the injury level. Chest wall expansion ceased to function, and the patient was breathing using only his diaphragm. The loss of his chest wall component of ventilation explains why he eventually tired to the point of requiring an invasive, surgical airway.

Conclusion

The EMS incident commander activated air medical transport for this patient as part of his initial scene size-up. Smooth, rapid transport to a trauma center well versed in spinal trauma, coupled with the advanced care capabilities of the flight physician/nurse team, was appropriate. It's worth noting the rapid escalation in resources required to care for this patient upon making this decision. En route to

the call, a single ambulance and crew seemed reasonable. Subsequently, two EMS crews, fire personnel for extrication and to manage the helicopter landing zone, and police at both sites were necessary.

Creative problem solving and multidisciplinary team work resulted in efficient, optimal prehospital care for this patient. There was a significant potential for iatrogenic injury or death, which was prevented by the crew's recognition of the seriousness of the initial injury, innovative underside cribbing/stabilization and careful handling of the patient by experienced personnel.

Encountering patients with a potential for cervical spine injury is a common occurrence in EMS. It's important that crews not become complacent or cavalier in their management of these patients. Although many patients may safely have their cervical spine "cleared" in the field, it's crucial to adhere to protocol to minimize the risk of negligently precipitating, or exacerbating, a devastating injury. **JEMS**

Jay Carter is an emergency medicine physician and the medical director for Hudson EMS. He has in excess of 30 years' experience in prehospital care, serving as an EMT, a flight surgeon and a medical director.

David Enzman is a 30-year EMS veteran with Cleveland EMS, serving as a chief paramedic and field training officer. Enzman served as EMS incident commander for this incident. He's also the acting fire chief of Northfield Center (Ohio) Fire Department.
